



# Colloidal silver for lung disease in cystic fibrosis

VR Baral • AL Dewar • GJ Connett

Regional Cystic Fibrosis Service, Southampton General Hospital, Tremona Road, Southampton, SO16 6YD

Correspondence to: Dr Gary Connett. E-mail: garyconnett@suht.swest.nhs.uk or Dr VR Baral. E-mail: vrbaral@yahoo.co.uk

## DECLARATIONS

### Competing interests

None declared

### Funding

None

### Ethical approval

Not applicable

### Guarantor

VRB

### Contributorship

All authors contributed equally

### Acknowledgements

None

## Introduction

Cystic Fibrosis (CF) families commonly consider alternative or complimentary therapies of questionable value. We report the case of a 12-year-old boy with severe CF lung complications who was treated by his family with colloidal silver.

## Case report

The child was diagnosed aged two (homozygous  $\Delta F508$ ) following investigations for faltering growth. He had extensive left lower lobe bronchiectasis and positive *Pseudomonas aeruginosa* cultures at diagnosis. This organism persisted despite aggressive IV antibiotics, long term nebulized colomycin, bronchoscopy and a prolonged in-patient stay. Aged three he developed pseudomembranous colitis requiring prolonged intensive care. Aged six he developed severe, steroid-dependent, relapsing allergic broncho-pulmonary aspergillosis (ABPA) and right mid-zone bronchiectasis. Atopic asthma also proved increasingly problematic, with evidence of sensitization and wheezing in relation to several aeroallergens, including house dust mite and cat. He had a significant step up in FEV1 after a trial of rhDNase (pulmozyme) and this drug was added to his treatment regime. Spirometry plateaued around 60%, with frequent deteriorations caused by wheezing episodes and infective exacerbations. Aged 10 his FEV1 deteriorated to 40% predicted with severe episodic wheeze. A Brompton referral was made

to consider monthly IVIG therapy (not given) and regular IV antibiotics and aggressive ABPA treatment were recommended.

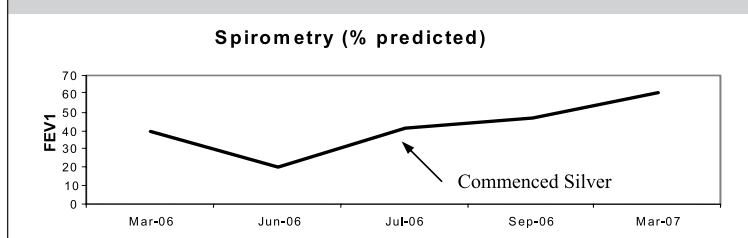
Aged 11, the patient isolated *Burkholderia multivorans* and *Stenotrophomonas maltophilia*. Pulmonary status deteriorated to an FEV1 of 24%. In March 2006, he was treated with prolonged IV and oral antibiotics, steroids and antifungals. Lung function recovered to around 40% but he remained markedly symptomatic, with persistent cough, breathlessness and wheeze after physical activity. Because of these complications he was referred for heart-lung transplant assessment.

At the same time, the family discovered websites promoting colloidal silver for CF and purchased the product from their local health food shop. They independently commenced 2.5 mL b.i.d. of the solution in July 2006. Over the next three months the patient achieved a sustained improvement in symptoms, which persisted following weaning from oral steroids, nebulized antibiotics and regular asthma medications. He has continued rhDNase treatment. FEV1 peaked at 60% (Figure 1). The family declined transplant assessment. He remained well for a year, enjoying a skiing holiday, full participation in school rugby matches and significant improvements in his golf handicap. He required only one further course of IV antibiotics until a recent deterioration coinciding with temporary interruption of colloidal silver for a month. Whereas sputum samples had consistently isolated *B. multivorans* before receiving silver, there had only been one further positive isolate during the year when he received it. He has remained well for a further six months after resuming colloidal silver, with no other changes in his routine care.

## Discussion

Silver is a xenobiotic absorbed from skin and mucous membranes of the gastrointestinal and urogenital tracts and lungs. It is excreted from the

**Figure 1**  
FEV1 over time



body in the urine and faeces. It was one of the first 'antibiotics' in medicine and remains in use in the treatment of burns and wound care. It is also a constituent in heart valve, orthopaedic and dental prostheses. Colloidal silver use declined markedly following the discovery of penicillin and sulphonomides, reports of argyria (i.e. staining of the skin with silver sulphide and silver selenide) and questionable efficacy. Case reports have described possible nephrotoxicity and neurotoxicity,<sup>1</sup> but these have not been substantiated by studies in animal models.<sup>2</sup> It has been superseded by silver sulphadiazine and sustained-release dressings in wound care.

Silver is freely available via the Internet and health food shops as an oral preparation. The actual dose in preparations that are available is unregulated and there are continuing risks of argyria. A recent case report has described skin discoloration in an 11-year-old boy with CF following ingestion of colloidal silver to facilitate limit of normal. Fortunately in this case the discoloration was transient and the silver level normalized following discontinuation of therapy.<sup>3</sup> In our case we have documented significant improvements in well-being that were temporally associated with the use of the drug. However, this is a single anecdote and caution should be used in interpreting the significance of these observations. If there was a direct clinical effect of the silver we speculate that this might have been as a result of a bactericidal action on CF pathogens, as suggested

by the decreased occurrence of *B. multivorans* on sputum cultures. Researchers in Denmark have shown that silver is highly effective as a bactericidal agent against biofilm and planktonic models of Gram-negative organisms, including *P. aeruginosa*.<sup>4</sup> Currently there is no evidence to support the use of silver products in CF but their potential benefits might be worthy of further exploration. An American study has shown benefits for silver in the treatment of *Burkholderia dolosa* infection in a murine model of severe lung sepsis.<sup>5</sup> Further *in vitro* studies of the effects of silver on the organisms within CF sputa and a better understanding of safe dosaging are essential first steps in exploring the potential for this use of this treatment option.

## References

- 1 Westhofen M, Schafer H. Generalised argyrosis in man: neurological, ultra structural and x-ray micro analytical findings. *Arch Otorhinolaryngol* 1986;**24**:260-4
- 2 Lansdown AB. Critical observations on the neurotoxicity of silver. *Crit Rev Toxicol* 2007;**37**:237-50
- 3 Baker CD, Federico MJ, Accurso FJ. Skin discoloration following administration of colloidal silver in cystic fibrosis. *Curr Opin Pediatr* 2007;**19**:733-5
- 4 Bjamsholt T, Kirketerp-Moller K, Kristiansen S, *et al.* Silver against *Pseudomonas aeruginosa* biofilms. *APMIS* 2007;**115**:921-8
- 5 Cannon CL, Capps GH, Hogue L, *et al.* A07: A murine model of *Burkholderia dolosa* pulmonary infection and treatment with a nebulised silver carbene compound. Abstracts of the International Burkholderia cepacia Working Group Meeting April 2005; Oklahoma, USA. <http://www.go.to/cepacia>